



PRESENTING CLINICAL SIGNS

DATE History: Grade II/VI murmur. Asymptomatic. Receiving pimobendan.

6/20/23 **ECHOCARDIOGRAPHIC FINDINGS**
2D, M-mode, and Doppler study.

PERFORMED BY: There is mild left atrial dilation. The mitral valve leaflets are mildly thickened and exhibit systolic prolapse. A mild to moderate jet of mitral regurgitation is present. There is mild left ventricular dilation. Left ventricular systolic function is hyperdynamic. The aorta and aortic valve are normal. Right atrial and right ventricular dimensions are normal. The tricuspid valve leaflets are mildly thickened, and a mild jet of tricuspid regurgitation is present. TR velocity does not suggest the presence of pulmonary hypertension. The pulmonary artery and pulmonic valve are normal. No pericardial effusion or cardiac masses are seen.

Shari Reffi, CVT

INTERPRETED BY

Keith Blass, DVM,
MS, DACVIM
(Cardiology)

LA - 34.5 mm
LVIDd - 34.9 mm
LVIDs - 18.5 mm
FS - 47%
RA - 20.8 mm
LVOT - 0.99 m/s
RVOT - 0.52 m/s
TR - 2.79 m/s

PATIENT

Abigail Burke

SPECIES

Canine

ASSESSMENT/RECOMMENDATIONS
Degenerative mitral and tricuspid valve disease

BREED

CKCS

SEX

FS

This examination demonstrates regurgitation of blood across Abigail's mitral and tricuspid valves resulting from degenerative valve disease. Abigail's tricuspid valve disease is mild, and appears to be well-compensated at this time. Her mitral valve disease is a bit more advanced, as Abigail has mild to moderate mitral regurgitation present, with mild secondary dilation of both her left atrium and left ventricle, though her left ventricular systolic function is well-preserved. As only mild left heart chamber dilation is present, Abigail's current risk for the development of clinical signs secondary to her mitral valve disease, such as coughing, exercise intolerance, syncope, and labored breathing, appears to be relatively low, though careful monitoring for these signs is recommended going forward.

AGE

11 y

Abigail's current therapy with pimobendan is warranted at this stage of disease. No other cardiac therapy is recommended at this time.

A recheck echocardiogram is recommended in 9 months. Thoracic radiographs are recommended if Abigail experiences respiratory clinical signs.

WEIGHT

28.8 lb

HOSPITAL NAME

Summit Dog and Cat
Hospital

REFERRING VET

Dr. Ardennies



DATE

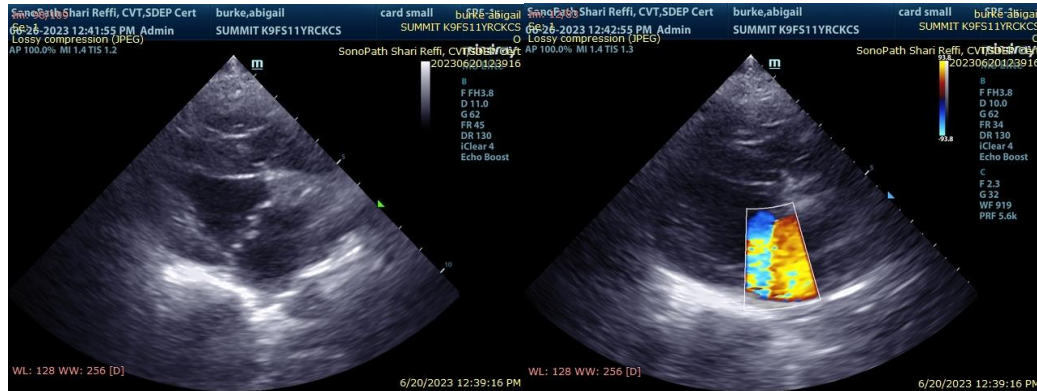
6/20/23

PERFORMED BY:

Shari Reffi, CVT

INTERPRETED BY

Keith Blass, DVM,
MS, DACVIM
(Cardiology)



PATIENT

Abigail Burke

The information and recommendations provided are based on the images presented by the referring veterinarian. No evaluation can be communicated regarding pathology that was not visible in the image/video clips provided.

Thank you for this referral. If the clinical or image interpretation does not parallel your findings or if I can be of any further assistance please contact me.

SPECIES

Canine

Keith Blass, DVM, MS, DACVIM (Cardiology)
KeithBlass@gmail.com
631-804-5754

BREED

CKCS

SEX

FS

AGE

11 y

WEIGHT

28.8 lb

HOSPITAL NAME

Summit Dog and Cat
Hospital

REFERRING VET

Dr. Ardennies